

New Method to Assess Scapular Upward Rotation in Subjects With Shoulder Pathology

Michael P. Johnson, PT, MS, OCS¹

Philip W. McClure, PT, PhD²

Andrew R. Karduna, PhD³

Study Design: Test-retest repeated measures and correlational design.

Objectives: To examine the reliability and validity of a "modified" digital inclinometer to assess scapular upward rotation during humeral elevation in the scapular plane

Background: Evidence exists that scapular motion is related to shoulder pathology; however, evaluation and treatment planning for shoulder rehabilitation often fails to include an objective assessment of scapular motion.

Methods and Measures: Two-dimensional measurements by the inclinometer were taken with the arm in a static position. These data were compared to 3-dimensional measurements obtained using a magnetic tracking device with the arm fixed and during arm movement. Both methods were used to assess scapular upward rotation positions with the arm at rest and at 60°, 90°, and 120° of humeral elevation in the scapular plane. Both scapulae were tested on a total of 39 subjects, 16 with shoulder pathology and 23 without. Reliability was assessed using repeated measurements from the inclinometer. Validity was assessed using 2 separate comparisons: inclinometer and magnetic tracking device under static arm conditions and inclinometer and magnetic tracking device during active arm elevation. Reliability and validity were assessed at all 4 arm positions.

Results: Intraclass correlation coefficients (ICC [3,1]) varied from 0.89 to 0.96. Pearson Product Moment correlation coefficients, used to assess validity of the static inclinometer, varied from $r = 0.74$ to 0.92 compared with the static magnetic tracking measures, and from $r = 0.59$ to 0.73 compared with the active magnetic tracking measures taken during arm elevation.

Conclusions: The "modified" digital inclinometer demonstrated good to excellent intrarater reliability and good to excellent validity when measuring scapular upward rotation during static positions of humeral elevation in the scapular plane. *J Orthop Sports Phys Ther* 2001; 31:81-89.

Key Words: inclinometer, measurement, scapular kinematics, scapular plane, three-dimensional

¹ Assistant professor, Department of Physical Therapy, University of the Sciences in Philadelphia, Philadelphia, Pa; Clinical Specialist, Mercy Fitzgerald Outpatient Center, Darby, Pa.

² Associate professor, Department of Physical Therapy, Beaver College, Glenside, Pa.

³ Associate professor, Department of Rehabilitation Sciences, MCP Hahnemann University, Philadelphia, Pa.

Approved by the institutional review board at MCP Hahnemann University.

Send correspondence to Michael P. Johnson, University of the Sciences in Philadelphia, Department of Physical Therapy, 600 South 43rd Street, Philadelphia, PA 19104-4495. E-mail: m.johnso@usip.edu

The shoulder complex allows the greatest amount of mobility of any joint in the body and also provides a stable base for the entire upper extremity. Coordinated scapulothoracic and glenohumeral movements during arm elevation, known as scapulohumeral rhythm,¹² provide range of motion while allowing for proper length-tension relationships between various axioscapular and glenohumeral muscles. Controversy exists about the overall ratio of movement between the glenohumeral and scapulothoracic articulations, as well as changes in the ratio throughout the arc of motion during arm elevation.^{8,10,12,24,29} The scapulohumeral rhythm was previously accepted as an approximate 2:1 ratio between glenohumeral elevation and scapular upward rotation. The ratio, however, is more complex than originally described by Inman¹² and is affected by such things as velocity of motion,²⁵ plane of elevation,²⁴ and external load.^{24,25}

The role of the scapula has generated much discussion about shoulder dysfunction.^{13,21,23,27,35,38} Changes in the scapular rest posi-

enus
om the
the first
ibclavi-
orta and
the
cava

ep to
ular
le,^{7,13,16}

lic

ses in
anterior
ular
,^{13,16}

es.
sually
s not
igual,
ies.
the
osteri-

scalen-
scalenus

/ and

sses of
of the

mus-
he ster-
o the
me to
ack of
of the
rohyoid

if the

er 3
om the
ower
es of the
6

(lateral
ect of the

TABLE 1. Descriptive statistics (mean \pm standard deviation) for all subjects included in the data analysis.

Subjects	n	Age (y)	Height (cm)	Weight (kg)	Hand dominance
Nonimpaired	23	32 \pm 10	168 \pm 9	63 \pm 14	Right = 20 Left = 3
Pathology	16	38 \pm 11	177 \pm 10	87 \pm 15	Right = 10 Left = 6
Combined	39	35 \pm 11	172 \pm 10	73 \pm 18	Right = 30 Left = 9

tion³⁵ and scapular motion^{21,38} have been implicated as potentially contributing to shoulder dysfunction. Some of these changes have been observed in subjects with impingement syndrome³⁸ and rotator cuff tears.²⁷ Matsen and Arntz²⁵ suggest that restricted scapulothoracic motion may, over time, lead directly to rotator cuff impingement and an eventual partial- or full-thickness tear of the rotator cuff tendons. Alterations in scapular position and motion may also contribute to glenohumeral instability.^{13,38} These factors emphasize the need to consider scapular motion during rehabilitation of the shoulder complex.

Early studies described the relationship between glenohumeral and scapulothoracic motion using static 2-dimensional (2-D) radiographs^{10,12,29} or goniometers.⁸ A 2-D analysis limits the ability to observe 3-dimensional (3-D) motion occurring within the shoulder complex and may poorly define scapular motions.⁵ Researchers have begun to use static and dynamic 3-D motion analyses to assess scapulohumeral kinematics,^{15,16,20,21,24} but few of these 2-D or 3-D methods are easily applied in the clinical setting.

A standard physical therapy evaluation of the shoulder observes the amount and quality of scapular motion during arm elevation.^{17,22} Presently, clinical assessments of scapular positions and motion with the arm at rest and during elevation have been qualitative.^{2,3,39} Recently, attempts have been made to quantitatively assess scapular positions using simple, clinical devices.^{7,11,19,26,28,34,36,40} Most of these studies assessed methods to measure the scapular rest position and demonstrate good to excellent intrarater and interrater reliability.^{7,11,19,26,34,36} A few studies^{9,40} have addressed the reliability of universal goniometers to assess the static position of the scapula through the range of arm elevation; however, this method appears unreliable.⁴⁰ Furthermore, no studies have attempted to validate a clinically applicable 2-D measurement method that assesses the position of the scapula.

We sought to answer the following questions regarding the assessment of scapular upward rotation positions during humeral elevation in the scapular plane: (1) what is the intrarater reliability of using a "modified" digital inclinometer; (2) what is the concurrent validity, under static arm conditions, between a digital inclinometer and a 3-D electromagnetic

tracking system; and (3) what is the criterion-related validity between a digital inclinometer, under static arm conditions, and a 3-D electromagnetic tracking system under dynamic arm conditions?

METHODS

Subjects

Thirty-nine subjects with ($n = 16$) and without ($n = 23$) a history of shoulder pathology were recruited from a sample of convenience. Table 1 provides descriptive information about the subjects. Patients were solicited from local outpatient physical therapy clinics, and subjects without pathology were solicited from within the student-faculty population at MCP Hahnemann University and the general public.

Inclusion criteria for subjects with shoulder pathology were (1) a diagnosis of shoulder pathology determined by an orthopaedic surgeon, (2) at least 120° of active arm elevation, and (3) examination of the patient by a physical therapist would normally include active range of motion measurements for shoulder elevation. Exclusion criteria included (1) congenital defect of the scapula (ie, Sprengel's deformity), (2) history of trauma or surgery to the rib cage or thoracic spine, or (3) known neuromuscular disorders.³⁴ Most subjects were diagnosed as having shoulder impingement syndrome, rotator cuff tears, or glenohumeral instability.

Subjects without shoulder pathology had no history of a shoulder or cervical pathology requiring medical evaluation. Exclusion criteria were the same as for subjects with shoulder pathology. All subjects signed a written consent and the MCP Hahnemann University Internal Review Board approved the use of human subjects for this study.

Two-dimensional Measurements

A Pro 360 digital protractor (inclinometer) (Macklanburg Duncan, Oklahoma City, Okla) was used to assess static positions of scapular upward rotation. The inclinometer is capable of measuring angles from a horizontal reference and is designed to be accurate within 0.1°.

The inclinometer was modified using 2 wooden lo-

nance

20
3
10
6
30
9

r-related
static
tracking

hout (*n*
recruited
des de-
ents
therapy
solicited
MCP
ic.
r pathol-
gy deter-
st 120°
of the
ly in-
for
ed (1)
l's defor-
e rib
muscular
having
ff tears,

to histo-
ing med-
me as
ects
emann
he use of

) (Mack-
used to
ation.
gles
to be ac-

oden lo-

bruary 2001




FIGURE 1. "Modified" Pro 360 digital protractor. Both wooden locator rods were attached to the device during testing.

ator rods, approximately 10 cm in length, which were attached to the bottom of the instrument (Figure 1). Each rod had square and Y-shaped ends. The square end, when connected to the inclinometer, permitted adjustment (rotation) of the distal end to different widths of the subjects' scapulae. Prior to testing with the inclinometer, the locator rods were adjusted to the length of the scapular spine by moving the 2 Y-shaped ends over the root of the scapular spine and posterolateral acromion. A small bubble level was attached to the left side of the inclinometer (Figure 1). This level was used to determine anterior-posterior rotation of the device about an axis parallel to the scapular spine. Maintaining the body of the inclinometer in a plane perpendicular to the horizontal plane is important because previous research indicates that anterior/posterior rotation or "out-of-plane" movement will increase error in digital inclinometer measurements.³¹ Data from the inclinometer were recorded on separate forms for each bout of testing.

Four arm positions were assessed: arm at rest, 60°, 90°, and 120° of static humeral elevation in the scapular plane. All of the arm positions are clinically relevant and consistent with previous literature.^{2,17,18,39} The number of humeral positions tested was limited to minimize time and improve the potential for clinical application of the method. McQuade et al²⁴ propose that the plane of humeral elevation used may influence the scapulohumeral rhythm. In our study, humeral elevation in the scapular plane was chosen because it has been suggested as the most functional plane for arm elevation.³² Use of the scapular plane for assessment of shoulder kinematics^{8,20,21,24,29,39} and rehabilitation of the shoulder complex^{14,17,40} has been most common in the literature.

Three-dimensional Measurements

A magnetic tracking device (Polhemus 3Space FasTrak, Colchester, Vt) was also used to assess static

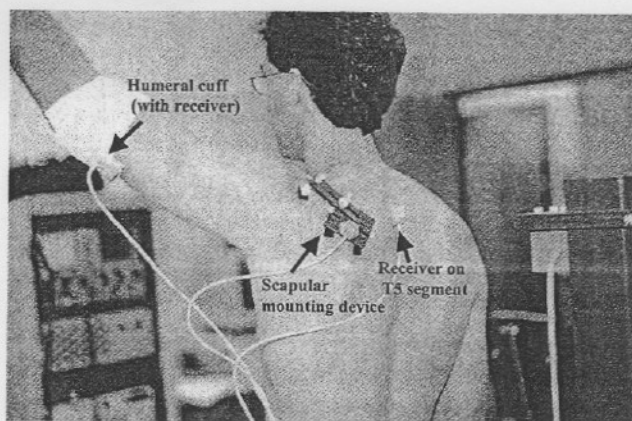


FIGURE 2. Measurements taken with the magnetic tracking device during 3 bouts of dynamic arm elevation in the scapular plane.

positions of scapular upward rotation. It is capable of assessing bony position and orientation in 3 planes (6 degrees of freedom).¹ Small sensors that are mounted on bony segments act as receivers and detect an electromagnetic signal emitted from a transmitter that is attached to a stationary base. Each receiver is capable of detecting position and orientation in 3 dimensions.

Raw data collected from the magnetic tracking device were converted to rotations with respect to anatomically appropriate coordinate axis systems, as previously described.¹⁶ A summary of this procedure can be found in the appendix. Three scapular rotations were collected, but only 1 (upward rotation) was used in this study. For the purposes of this study, a global reference frame defined by a transmitter and local reference frames located on the humerus and scapula were used. Lightweight receivers were mounted to the skin overlying the humerus (just proximal to the medial-lateral epicondyles) and scapula (along the scapular spine) with the use of plastic mounting devices, straps, and adhesive tape (Figure 2). The scapular-mounted device was shown to be valid for assessing 3-D scapular kinematics using surface sensors in a previous study.¹⁶ In that study, output from a skin-mounted sensor was compared with output from a sensor that was mounted on pins surgically implanted into the scapula of 8 nonimpaired subjects during a wide range of shoulder motions. The investigators found a mean error of 3.5° when assessing scapular upward rotation during scapular plane motion. Raw data from the magnetic tracking device were fed into the serial port of a personal computer and processed using LabView 3.1 (National Instruments, Austin, Tex) and Microsoft Excel 5.0 (Microsoft, Inc, Redmond, Wash) software. Both 3-D and 2-D methods measure humeral and scapular motion with respect to cardinal planes (global reference) instead of with respect to another bony segment such as the thorax (anatomic reference).

In addition to the static positions described above,

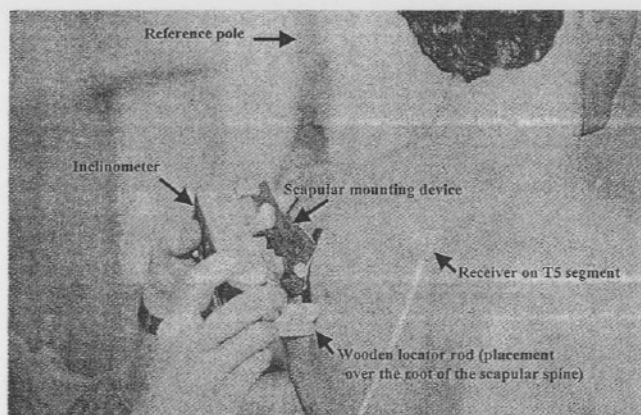


FIGURE 3. Concurrent measurements of scapular upward rotation using the inclinometer and magnetic tracking device with the arm held at 90°.

the magnetic tracking device was also used continuously to assess dynamic scapular upward rotation during humeral elevation. These measurements were taken during the same test session and consisted of active arm elevation through the subjects' full range of humeral elevation in the scapular plane.

Procedure

Subjects were asked to stand in a normal, relaxed posture and elevate the arm as far as possible. A pole placed on a line, angled 40° from the frontal plane of the subject, insured positioning of the arm in the scapular plane. Subjects were instructed to keep their hand open with their thumb pointing toward the ceiling when tested at the 60°, 90°, and 120° humeral positions. Placement of the inclinometer over the midshaft of the humerus was used to determine positions of 60°, 90°, and 120° of humeral elevation prior to each measurement. Subjects maintained hand position in relation to dash marks on the pole while measurements were taken (approximately 10–15 seconds) and were then instructed to relax. A rest period of 5 seconds was allowed before initiating measurements at another position.

Prior to each test session, the following variables were randomized and their order of testing was marked on the data collection sheet: (a) test arm (left or right); (b) test position (arm at rest, 60°, 90°, and 120°); and (c) test type (static versus dynamic).

The 3 types of testing during an overall measurement session included the following: (a) Two measurements each, from both the inclinometer and magnetic tracking device, were taken alternately at each static arm position (Figure 3); (b) Two measurements, using only the inclinometer, were taken separately at each static arm position (Figure 4) which occurred either 20 minutes before or after the previously described testing; (c) Dynamic measurements, using only the magnetic tracking device, were taken either prior to or directly following the static

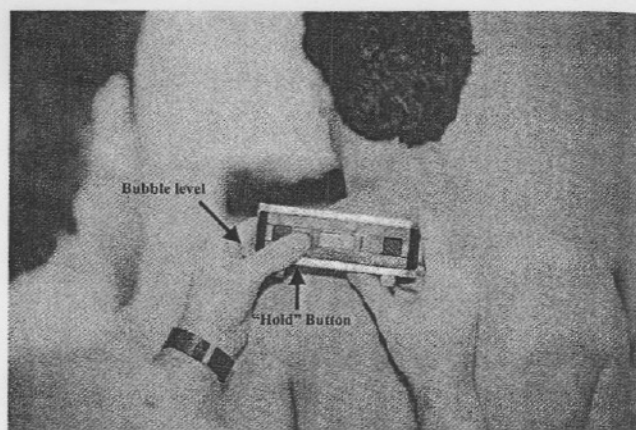


FIGURE 4. Measurements taken with the inclinometer with the arm held in the rest position.

measurements (Figure 2). Subjects were asked to elevate the test arm from the rest position through their full range of motion once or twice as a practice motion. The speed of arm motion was controlled using a verbal cadence of 3 seconds for humeral elevation and depression. Data were collected during 3 bouts of dynamic, active arm elevation. A rest period of 30 seconds was allowed after the completion of a test before initiating another test.

Data Analysis

Mean scores derived from 2 measurements (static testing) or 3 measurements (dynamic testing) at each arm position (rest, 60°, 90°, and 120°) were used for data analysis. Subjects were used as a single group and were not separated based on type or presence of shoulder pathology. Paired *t* tests were performed to compare differences between the dominant and non-dominant arms at each arm position. Comparisons were made between arms for each of the 3 measurement methods: inclinometer, magnetic tracking device (static), and magnetic tracking device (dynamic). A Bonferroni adjustment was made to correct for alpha level inflation due to multiple *t* tests being performed. The adjusted significance level was $P < .0125$ (.05/4).

Intraclass correlation coefficients (ICC [3,1]),³³ means, standard deviations, standard errors of the mean (SEM), and 95% confidence intervals (CI) for the correlation coefficients were assessed at each of the 4 humeral positions based on the inclinometer data. Intraclass correlation coefficient calculations were based on a repeated measures ANOVA design with 2 measurements across 39 subjects.³⁰

Pearson Product Moment correlation coefficients and regression equations were used to compare static inclinometer with static magnetic tracking device and static inclinometer with dynamic magnetic tracking device measurements at all 4 arm positions.

Most data analyses were performed using the SPSS

TABLE 2. Intrarater reliability for dominant and nondominant arms at each static position using the inclinometer.

Arm position	Arm	Trial 1* Mean (SD)	Trial 2* Mean (SD)	ICC (3,1)	95% CI	SEM*
Rest	D	2.9 (6.5)	2.1 (6.3)	0.90	0.82-0.95	2.0
	ND	3.4 (5.8)	2.8 (6.1)	0.89	0.80-0.94	2.0
60°	D	9.5 (8.9)	11.3 (9.7)	0.91	0.84-0.96	2.8
	ND	10.8 (7.4)	11.1 (8.0)	0.89	0.80-0.94	2.5
90°	D	21.9 (10.5)	22.5 (11.2)	0.94	0.89-0.97	2.6
	ND	22.7 (6.7)	23.3 (6.8)	0.89	0.80-0.94	2.2
120°	D	37.8 (9.7)	38.6 (10.1)	0.96	0.93-0.98	2.0
	ND	39.9 (6.9)	39.9 (6.8)	0.90	0.82-0.95	2.1

CI indicates confidence interval; D, dominant; ND, nondominant; SEM, standard error of the mean.

* All units are in degrees.

(version 7.5.1) for Windows statistical package (SPSS, Inc, Chicago, Ill). Intraclass correlation coefficient values were calculated using a custom DOS-based statistical program.

RESULTS

Both shoulders were tested on all 39 subjects (Table 1), except in 3 cases where 1 arm did not meet the inclusion criteria. Paired *t* tests revealed no significant differences ($P > .0125$) between the dominant and nondominant arms at all 4 positions of humeral elevation in the scapular plane. Statistical assumptions of data distribution were assessed and met the criteria for all analyses performed.

Intraclass correlation coefficient (3,1) values for intrarater reliability using the inclinometer to assess scapular upward rotation at the 4 humeral positions, varied from 0.89 to 0.96 (Table 2). ICCs were higher for the dominant versus nondominant scapula. These

TABLE 3. Comparisons between scapulae using the 2-D inclinometer and 3-D magnetic tracking device measurement methods.

Arm position	Arm	r*	Slope	Intercept†	MD†
Static					
Rest	D	0.86	1.20	6.7	7.0
	ND	0.86	1.20	8.5	9.5
60°	D	0.92	1.20	6.4	8.5
	ND	0.79	0.94	8.4	7.7
90°	D	0.88	0.97	13.0	12.2
	ND	0.78	0.98	12.0	10.9
120°	D	0.85	0.92	18.0	14.4
	ND	0.74	1.10	9.1	12.9
Dynamic					
Rest	D	0.72	0.93	10.0	10.0
	ND	0.69	1.10	11.0	11.2
60°	D	0.73	0.69	16.0	12.6
	ND	0.59	0.74	16.0	12.9
90°	D	0.73	0.65	21.0	12.6
	ND	0.63	0.86	16.0	13.1
120°	D	0.72	0.73	22.0	10.9
	ND	0.73	1.10	4.0	10.1

MD indicates mean difference; D, dominant; ND, nondominant.

* Pearson Product Moment correlation coefficient.

† All units are in degrees.

values improved for both arms as humeral elevation increased and were greatest at the 120° position.

Table 3 lists Pearson Product Moment correlation coefficients comparing use of the inclinometer to the magnetic tracking device under static and dynamic conditions. Static comparisons between both instruments ($r = 0.74-0.92$) showed a better correlation than did static inclinometer measures compared with magnetic tracking device measurements taken dynamically ($r = 0.59-0.73$). Also, correlation coefficients were consistently higher for the dominant arm during both comparisons.

DISCUSSION

The inclinometer demonstrated good to excellent intrarater reliability within a single session at all 4 levels of humeral elevation in the scapular plane (ICC [3,1] = 0.89 to 0.96). The ICC model 3,1 was specifically chosen because it is the most appropriate for assessing intrarater reliability.^{30,33} For both arms at all humeral levels, the 95% confidence intervals of the ICC were within the range of good to excellent reliability (0.80-0.98) and standard errors of measurement were less than 3° (Table 2).

The reliability of assessing scapular positions using simple, clinically available measurement methods has been addressed in the literature.^{7,11,19,26,34,40} However, most research studies have only assessed the scapular rest position, while our study examined 4 positions. Our results compared well with previous research with respect to intrarater reliability of assessing the scapular rest position (Table 4). However, all the listed studies used nonimpaired subjects who had no history of shoulder pathology. The generalizability of their findings is limited to that of a nonimpaired population, whereas our study included subjects with a range of common shoulder pathologies. We chose to include subjects with and without shoulder pathology because a standard physical therapy examination of joint mobility will typically assess both the involved and uninvolved joints.

The lateral scapular slide test, as described by Kibler¹⁹ and modified by Davies et al,⁴ measures the

the arm held

sed to ele-
ough
a practice
trolled us-
eral eleva-
uring 3
est period
tion of a

nts (static
ig) at each
: used for
: group
resence of
formed to
t and non-
comparisons
measure-
-ing de-
(dynam-
correct for
being per-
; $P <$

3,1]),³³
s of the
s (CI) for
t each of
nometer
lations
A design

efficients
pare static
device and
tracking
i.
g the SPSS

TABLE 4. Intrarater reliability. Comparison of different methods to assess the scapular rest position.

Author	Side	Method	Instrument (unit of measurement)	Reliability coefficient	Statistical test
DiVeta ⁷	D	Distance from T3 to inferior angle of the acromion	String (cm)	0.94	ICC (1,1)
Gibson ¹¹	D	Distance from T3 to inferior angle of the acromion	String (cm)	0.92-0.95	ICC (2,1)
	ND			0.93-03.95	
T'Jonck ³⁶	D	Distance from T3 to inferior angle of the acromion	String (cm)	0.90	ICC (?)
	ND			0.89	
Gibson ¹¹	D	Distance between thoracic spine and medial border of the scapula	Tape measure (cm)	0.92-0.94	ICC (2,1)
	ND			0.91-0.93	
T'Jonck ³⁶	D	Distance between thoracic spine and medial border of the scapula	Tape measure (cm)	0.93	ICC (?)
	ND			0.83	
Sobush ³⁴	D	Distances between scapular landmarks and corresponding midline points	Scoliometer (cm)	0.96	ICC (2,1)
	ND			0.84	
Current study	D	Angle between the scapular spine and horizontal	Inclinometer (degrees)	0.91	ICC (3,1)
	ND			0.89	

D indicates dominant; ND, nondominant.

scapula at 5 different positions of humeral elevation. Substantive differences in the arm positions and a lack of reported reliability coefficients by Kibler¹⁹ and Davies⁴ make comparisons with our method difficult. However, the intrarater reliability of this method in assessing scapular rest position, as performed by Gibson et al,¹¹ has been presented (Table 4). The ICC values are slightly higher using the Kibler method, but their method relies on a linear measurement (centimeters) while our method uses an angular measurement (degrees) for assessing scapular rest position.

Doody et al⁹ presented data on scapular upward rotation measurements at 30°-increments of humeral elevation using a universal goniometer. Although the reliability of this method has been questioned,⁴⁰ the results provide the only other comparison of scapular positions at the same 4 humeral positions used in our study (Table 5). The study by Doody et al⁹ used a vertical reference and the scapular spine to measure scapular positions, while our study used a horizontal reference and the scapular spine. Therefore, the values from Doody et al,⁹ shown for comparison, were derived by subtracting 90° from the actual values reported. The differences in mean scapular position are less than 4° in all 4 humeral positions.

The inclinometer demonstrated good to excellent

TABLE 5. Comparison of methods to assess scapular upward rotation at 4 static humeral positions.

Arm position	Mean scapular position*		SD*	
	Doody ⁹	Current study	Doody ⁹	Current study
Rest	5.0	2.8	3.4	6.1
60°	14.6	10.7	5.3	8.5
90°	23.8	22.6	6.5	8.9
120°	40.7	39.1	6.9	8.4

* All units are in degrees.

concurrent validity under static conditions when compared with the magnetic tracking device. Although mean differences varied from 7° to 14°, the intercepts from the regression equation varied from 6° to 18° at each arm position (Table 3). These findings suggest that the differences are more likely due to systematic error than actual differences between the measurement methods. The inclinometer assessed scapular position using the scapular spine as a reference, while the magnetic tracking device used the acromion process. The use of different landmarks can result in similar changes in rotation, represented by dissimilar values.⁵ The slopes from the regression equations range from 0.92 to 1.20 at all 4 arm positions. This demonstrates a positive correlation in which there was a 0.92° to 1.20° increase in scapular upward rotation, as measured by the magnetic tracking device for each 1° change seen with the inclinometer, suggesting that the 2 methods are measuring similar changes in scapular upward rotation during humeral elevation in the scapular plane (Figures 5 and 6).

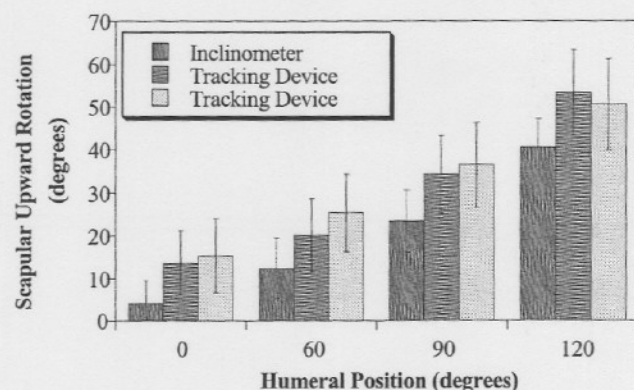


FIGURE 5. Nondominant scapular position (mean ± SD) at each humeral position using the 3 measurement methods.

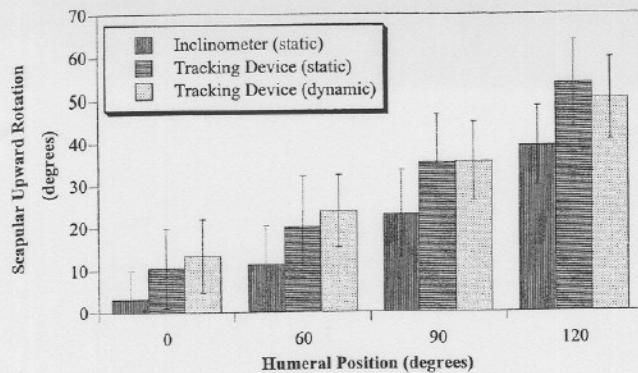


FIGURE 6. Dominant scapular position (mean \pm SD) at each humeral position using the 3 measurement methods.

Correlation coefficients were lower for the nondominant arm during reliability and validity testing under static conditions. This may be due, in part, to less variability amongst the nondominant arm data (see standard deviations in Table 2), since correlation coefficients are affected by the heterogeneity (ie, range of scores) within a data set.³⁰

The inclinometer demonstrated good criterion-related validity when compared with the measurements taken by the magnetic tracking device under dynamic conditions in assessing scapular upward rotation during humeral elevation in the scapular plane. Mean differences varied from 10.0° to 13.1°, while the intercepts and the slopes varied from 4.0° to 22.0° and 0.53° to 1.1° at the 4 arm positions, respectively (Table 3). These findings suggest that the 2 methods are measuring similar changes in scapular upward rotation. However, given the discrepancies between mean differences, intercepts and slopes (versus the static comparison), systematic error cannot fully account for the differences between the measurement methods. This is predominantly evident at the higher levels of elevation.

Figure 7 shows a scatter plot of the nondominant arm at 120° of humeral elevation under static and dynamic conditions. There is a pattern of less scapular upward rotation during dynamic testing with the magnetic tracking device (see Figures 5 and 6). Similar findings were seen by de Groot et al⁶ and Michiels and Grevenstein²⁵ when studying the effects of velocity on the scapulohumeral rhythm. This may be due to differing inertial forces and central nervous system demands present during dynamic arm elevation. Perhaps increased upward rotation of the scapula is required to maintain glenohumeral stability when the arm is held in a static overhead position. While further research is necessary, our study demonstrates that differences in scapular upward rotation during static versus dynamic arm elevation appear to exist, particularly at positions above 90° of humeral elevation.

A review of the literature revealed no research comparing a 2-D clinically applicable method with a

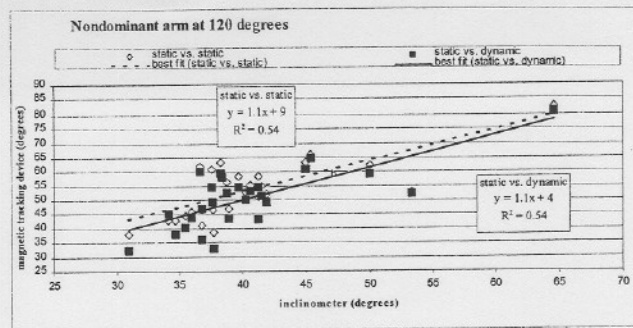


FIGURE 7. Scatterplots of nondominant arm data at 120° of humeral elevation comparing inclinometer (static) and magnetic tracking device (static and dynamic) measurements.

3-D method for assessing scapular motion. Therefore, we were unable to compare our findings with previous studies of this nature.

Our study was designed to measure intrasession interrater reliability. Interpretation of the results can be generalized only to one tester during one testing session. In order to be clinically applicable, a method must demonstrate excellent reliability among a variety of testers and across testing sessions (intersession interrater reliability).

Our study was limited to assessment of 2-dimensional scapular upward rotation using the inclinometer. Perhaps upward rotation is not the only (or the most important) scapular motion to consider with shoulder pathology. A few studies have assessed other scapular kinematic variables using clinically applicable methods.^{4,7,11,26,28,34} More research is needed to determine which motion or combination of scapular motions is most important to assess with patients who have shoulder pathology.

The tester in our study was not blinded to the measurements taken with the inclinometer. However, once the inclinometer was positioned, the tester could “freeze” the measurement using a “hold” button on the device. This diminished the need to monitor the digital readout, enabling the tester to focus on maintaining proper placement of the device. Separate data collection forms were used for each test session which allowed the tester to be blinded from the initial measurements. Nonetheless, lack of true tester blinding presents a limitation to this study.

Suggested areas of future research include interrater reliability and between groups testing on subjects with and without shoulder pathology. This should identify whether differences in scapular upward rotation exists. Reliability for assessing humeral range of motion, as well as motion of other body segments, could be an area for further investigation using the digital inclinometer.

CONCLUSION

The “modified” Pro 360 digital inclinometer demonstrated excellent intrarater reliability in assessing

stical test

(1,1)

(2,1)

(?)

(2,1)

(?)

(2,1)

(3,1)

then

Al-

14°, the

ed from

ese find-

kely due

etween

r as-

pine as a

re used

and-

on, rep-

m the

) at all 4

correla-

ease in

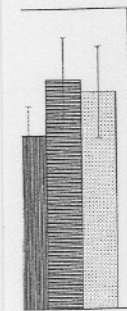
e mag-

n with

oods are

rd rota-

ar plane



120

each humeral

scapular upward rotation at 4 static positions of humeral elevation in the scapular plane. This level of reliability is limited to use of the instrument by one tester during the same testing session. The inclinometer has also demonstrated good to excellent concurrent validity, compared with a magnetic tracking device, in assessing scapular upward rotation. Further interrater reliability testing is warranted since intrarater reliability and concurrent validity have been established.

The inclinometer provides clinicians with a useful adjunct to glenohumeral goniometry during the assessment of shoulder motion. The objective information obtained from the inclinometer may improve the clinical assessment and documentation of patient progress, therefore enhancing our ability to effectively measure treatment outcomes.

ACKNOWLEDGEMENTS

The authors are very grateful to Dr Brian Sennett for his contributions and assistance throughout this project. We also thank Bill Bryant, ATC, Gus Ciardillo, MS, PT, Terri Handy, MSPT, ATC, and Krys Siwko, OTR/L, CHT for their assistance in the recruitment of subjects with shoulder pathology.

REFERENCES

- An K, Browne A, Korinek S, Tanaka S, Morrey B. Three-dimensional kinematics of glenohumeral elevation. *J Orthop Res.* 1991;9:143-9.
- Boublik M, Hawkins RJ. Clinical examination of the shoulder complex. *J Orthop Sports Phys Ther.* 1993;18(1):379-385.
- Culham E, Peat M. Functional anatomy of the shoulder complex [Review]. *J Orthop Sports Phys Ther.* 1993;18(1):342-350.
- Davies G, Dickoff-Hoffman S. Neuromuscular testing and rehabilitation of the shoulder complex. *J Orthop Sports Phys Ther.* 1993;18:449-458.
- de Groot J, Valstar E, Arwert H. Velocity effects on the scapulo-humeral rhythm. *Clin Biomech.* 1998;13:593-602.
- de Groot J. The scapulo-humeral rhythm: effects of 2-D roentgen projection. *Clin Biomech.* 1999;14:63-68.
- DiVeta J, Walker ML, Skibinski B. Relationship between performance of selected scapular muscles and scapular abduction in standing subjects. *Phys Ther.* 1990;70:470-476.
- Doody SG, Freedman L, Waterland JC. Shoulder movements during abduction in the scapular plane. *Arch Phys Med Rehabil.* 1970;51:595-604.
- Doody SG, Waterland JC, Freedman L. Scapulo-humeral goniometer. *Arch Phys Med Rehabil.* 1970;51:711-3.
- Freedman L, Munro RR. Abduction of the arm in the scapular plane: scapular and glenohumeral movements. *J Bone Joint Surg.* 1966;48A:1503-1510.
- Gibson MH, Goebel GV, Jordan TM, Kegerreis S, Worrell TW. A reliability study of measurement techniques to determine static scapular position. *J Orthop Sports Phys Ther.* 1995;21:100-106.
- Inman VT, Saunders M, Abbott LC. Observations on the function of the shoulder joint. *J Bone Joint Surg.* 1944;26:1-30.
- Itio E, Motzkin NE, Morrey BF, An K. Scapular inclination and inferior stability of the shoulder. *J Shoulder Elbow Surg.* 1992;1:131-139.
- Jobe FW, Moynes DR, Brewster CE. Rehabilitation of shoulder joint instabilities. *Orthop Clin North Am.* 1987;18:473-482.
- Johnson GR, Stuart PR, Mitchell S. A method for the measurement of three-dimensional scapular movement. *Clin Biomech.* 1993;8:269-273.
- Karduna AR, McClure PW, Michener LA, Sennett B. Dynamic measurements of three dimensional scapular kinematics: a validation study. *J Biomech Eng.* (in press).
- Kelly M, Clark W. *Orthopedic Therapy of the Shoulder.* Philadelphia, Pa: JB Lippincott Co; 1995.
- Kessel L, Watson M. The painful arc syndrome: clinical classification as a guide to management. *J Bone Joint Surg.* 1977;59B:166-172.
- Kibler WB. Role of the scapula in the overhead throwing motion. *Contemp Orthop.* 1991;22:525-532.
- Ludewig PM, Cook TM, Nawoczenski DA. Three-dimensional scapular orientation and muscle activity at selected positions of humeral elevation. *J Orthop Sports Phys Ther.* 1996;24:57-65.
- Lukasiewicz A, McClure P, Pratt N. Comparison of three-dimensional scapular position and orientation between subjects with and without shoulder impingement Syndrome. *J Orthop Sports Phys Ther.* 1999;29:574-583.
- Magee DJ. *Orthopedic Physical Assessment.* 2nd ed. Philadelphia, Pa: WB Saunders Co; 1992.
- Matsen FA, Arntz CT. Subacromial impingement. In: Rockwood CA, Matsen FA, eds. *The Shoulder.* Philadelphia, Pa: WB Saunders Co; 1990:623-646.
- McQuade KJ, Smidt GL. Dynamic scapulohumeral rhythm: the effects of external resistance during elevation of the arm in the scapular plane. *J Orthop Sports Phys Ther.* 1998;27:125-133.
- Michiels I, Grevenstein J. Kinematics of shoulder abduction in the scapular plane: on the influence of abduction velocity and external load. *Clin Biomech.* 1995;10:137-143.
- Neiers L, Worrell TW. Assessment of scapular position. *J Sport Rehab.* 1993;2:20-25.
- Paletta GA, Warner JJP, Warren RF, Deutsch A, Altchek DW. Shoulder kinematics with two-plane x-ray evaluation in patients with anterior instability or rotator cuff tearing. *J Shoulder Elbow Surg.* 1997;6:516-27.
- Plafcan DM, Turczany PJ, Guenin BA, Kegerreis S, Worrell TW. An objective measurement technique for posterior scapular displacement. *J Orthop Sports Phys Ther.* 1997;25:336-341.
- Poppen NK, Walker PS. Normal and abnormal motion of the shoulder. *J Bone Joint Surg.* 1976;58A:195-201.
- Portney L, Watkins M. *Foundations of Clinical Research: Applications to Practice.* Norwalk, Ct: Appleton & Lange; 1993.
- Reenders SJ, Tan CR. Validity and reliability of the Blankenship electronic inclinometer [abstract]. *J Orthop Sports Phys Ther.* 1998;27:59.
- Saha A. Mechanism of shoulder movements and a plea for the recognition of "zero position" of glenohumeral joint. *Clin Orthop.* 1983;173:3-10.
- Shrout P, Fleiss J. Intraclass correlations: uses in assessing rater reliability. *Psych Bulletin.* 1979;86:420-428.
- Sobush DC, Simoneau GG, Dietz KE, Levene JA, Grossman RE, Smith WB. The Lennie Test for measuring scapular position in healthy young adult females: a reliability

1944;26:
clination
ar Elbow
ation of
n. 1987;
the mea-
ent. Clin
tt B. Dy-
ular kin-
ress).
houlder.
: clinical
one Joint
throwing
e-dimen-
selected
hys Ther.
of three-
between
ent Syn-
583.
ed. Phil-
nent. In;
Philadel-
humeral
levation
orts Phys
r abduc-
bduction
10;137-
osition. J
Altchek
valuation
f tearing.
, Worrell
posterior
ar. 1997;
otion of
:01.
Research:
& Lange;
he Blan-
Orthop
d a plea
humeral
assessing
3.
, Gross-
ng scap-
eliability
uary 2001

- and validity study. *J Orthop Sports Phys Ther.* 1996;23:39-50.
35. Solem-Bertoft E, Thuomas KA, Westerberg CE. The influence of scapular retraction and protraction on the width of the subacromial space. An MRI study. *Clin Orthop.* 1993;296:99-103.
36. T'Jonck L, Lysens R, Grasse G. Measurement of scapular position and rotation: a reliability study. *Physiother Res Inter.* 1996;1:148-158.
37. Van der Helm F, Pronk G. Three-dimensional recording and description of motions of the shoulder mechanism. *J Biomech Eng.* 1995;117:27-40.
38. Warner JJP, Micheli LJ, Arslanian LE, Kennedy J, Kennedy R. Scapulothoracic motion in normal shoulders and shoulders with glenohumeral instability and impingement syndrome; a study using moire topographic analysis. *Clin Orthop.* 1992;85:191-199.
39. Wilk K, Arrigo C. Current concepts in the rehabilitation of the athletic shoulder. *J Orthop Sports Phys Ther.* 1993;18:365-375.
40. Youdas JW, Carey JR, Garrett TR, Shuman VJ. Reliability of goniometric measurements of active arm elevation in the scapular plane obtained in a clinical setting. *Arch Phys Med Rehabil.* 1994;75:1137-1144.

APPENDIX

The arbitrary axes defined by the magnetic tracking device were converted to anatomically appropriate embedded axes. For both the scapula and humerus, bony landmarks were used to define medial-lateral (ML), superior-inferior (SI), and anterior-posterior (AP) axes. The scapular ML axis was defined by a vector connecting the acromioclavicular joint and root of the scapular spine, the AP axis was defined by a vector perpendicular to the plane defined by these 2 points and the inferior angle and the SI axis was defined as the cross product of the first 2 axes. For the humerus, the SI axis was defined by a vector connecting the center of the humeral head to the midpoint between the medial and lateral epicondyles, the AP axis was defined by a vector perpendicular to the plane defined by these 3 points and the ML axis was defined as the cross product of the first 2 axes.

All landmarks were surface points and could thus be located directly with a digitizer connected to the magnetic tracking device, except for the center of the humeral head. This was defined as the point on the humerus that moved the least with respect to the scapula when the humerus was moved through short arcs (< 45 degrees) of midrange glenohumeral motion and was calculated using a least-squares algorithm.

Standard matrix transformation methods were used to determine the rotational matrix of the humerus and scapula with respect to the global reference frame.³⁷ Humeral rotations were represented using a standard Euler angle sequence in which the first rotation defined the plane of elevation, the second rotation described the amount of elevation, and the last rotation represented the amount of internal-external rotation.¹ Scapular rotations were represented using an Euler angle sequence of external-internal rotation (SI axis), upward-downward rotation (AP axis), and anterior-posterior tilting (ML axis).³⁷ Based on our previous study validating the accuracy of mounting a sensor on the scapula, a correction factor was developed¹⁶ and was used in our study.